1° ΠΑΝΕΛΛΗΝΙΟ ΣΥΝΕΔΡΙΟ
ΚΟΛΟΠΡΩΚΤΟΛΟΓΙΑΣ

# Λαπαροσκοπική δεξιά κολεκτομή tips & tricks

Βασίλειος Δρακόπουλος MD, PhD, FACS
Χειρουργός
Α' Χειρουργική Κλινική – Μονάδα Μεταμοσχεύσεων Οργάνων
Γ.Ν.Α. «ο Ευαγγελισμός»

## Λαπαροσκοπική Χειρουργική Αντιμετώπιση:

Η εξέλιξη της Χειρουργικής, σε συνδυασμό με την υψηλή τεχνολογία οδήγησαν στην καθιέρωση της λαπαροσκοπικής κολεκτομής που αποτελεί πλέον μια εδραιωμένη μέθοδο βάσει των αποτελεσμάτων που προκύπτουν από τη διεθνή βιβλιογραφία. Πρέπει όμως να εφαρμόζεται σε κέντρα που παρέχουν τον κατάλληλο λαπαροσκοπικό εξοπλισμό και κυρίως την έμπειρη χειρουργική ομάδα που κατέχει την αντίστοιχη καμπύλη εκπαίδευσης για κάθε επέμβαση προς αποφυγή επιπλοκών.

## Ιστορική Αναδρομή – Νεότερα Επιτεύγματα:

- Πρώτη εφαρμογή λαπαροσκοπικής κολεκτομής τον Οκτώβριο του 1990 από τον Dennis Fowler / **Fowler DL1, White SA, Laparoscopy-assisted sigmoid resection, Surg Laparosc Endosc 1991;1:183-188.**
- Λαπαροσκοπική κολεκτομή Μίας Τομής (SILS – Single Incision Laparoscopic Surgery) το 2008 από τους Remzi FH, Kirat HT, Geisler DP. / **Laparoscopic single-port colectomy for sigmoid cancer. Tech Coloproctol. 2010;14:253–255 Bucher P, Pugin F, Morel P. Single port access laparoscopic right hemicolectomy. Int J Colorectal Dis. 2008;23:1013–1016.**

Σύγχρονες τυχαιοποιημένες μελέτες (RCTs) έχουν αποδείξει ότι η λαπαροσκοπική κολεκτομή συνοδεύεται από καλύτερα βραχυπρόθεσμα αποτελέσματα συγκριτικά με την ανοικτή Χειρουργική.

## Βιβλιογραφία:


- Cianchi F1, Trallori G2, Mallardi B3, Macrì G4, Biagini MR5, Lami G6, Indennitate G7, Bagnoli S8, Bonanomi A9, Messerini L10, Badii B11, Staderini F12, Skalamera I13, Fiorenza G14, Perigli G15. Survival after laparoscopic and open surgery for colon cancer: a comparative, single-institution study. BMC Surg. 2015 Mar 25;15(1):33. doi: 10.1186/s12893-015-0013-5.
- Di Fabio F1, Barkhatov L2, Bonadio I3, Dimovska E4, Fretland ÅA2, Pearce NW4, Troisi RI5, Edwin B2, Hilal MA4. The impact of laparoscopic versus open colorectal cancer surgery on subsequent laparoscopic resection of liver metastases: A multicenter study. Surgery. 2015 Mar 30. pii: S0039-6060(15)00019-7. doi: 10.1016/j.surg.2015.01.007.
- Gorgun E1, Gezen FC, Aytac E, Stocchi L, Costedio MM, Remzi FH. Laparoscopic versus open fecal diversion: does laparoscopy offer better outcomes in short term? Tech Coloproctol. 2015 Mar 22.
- Hasegawa Y1, Nitta H2, Sasaki A2, Takahara T2, Itabashi H2, Katagiri H2, Otsuka K2, Nishizuka S2, Wakabayashi G2. Long-term outcomes of laparoscopic versus open liver resection for liver metastases from colorectal cancer: A comparative analysis of 168 consecutive cases at a single center. Surgery. 2015 Mar 16. pii: S0039-6060(15)00063-X. doi: 10.1016/j.surg.2015.01.017.
- Schietroma M1, Pessia B2, Carlei F1, Marina Cecilia E1, De Santis G1, Amicucci G1. Laparoscopic versus open colorectal surgery for colon cancer: the effect of surgical trauma on the bacterial translocation. A prospective randomized study. Am J Surg. 2015 Jan 14. pii: S0002-9610(15)00012-4. doi: 10.1016/j.amjsurg.2014.09.031.
- Baek JH1, Lee GJ1, Lee WS1. Comparison of long-term oncologic outcomes of stage III colorectal cancer following laparoscopic versus open surgery. Ann Surg Treat Res. 2015 Jan;88(1):8-14. doi: 10.4174/astr.2015.88.1.8. Epub 2014 Dec 26.
- Ng KH, Ng DC, Cheung HY, et al. Laparoscopic resection for rectal cancers: lessons learned from 579 cases. Ann Surg 2009 Jan;249(1):82–6.
- Wolfgang Schwenk, Oliver Haase, Jens J. Neudecker, Joachim M Müller. Short term benefits for laparoscopic colorectal resection. Review 2008 The Cochrane Collaboration.
- Veldkamp R, Kuhry E, Hop WC, et al; COlon cancer Laparoscopic or Open Resection study group (COLOR). Laparoscopic surgery versus open surgery for colon cancer: short-term outcomes of a randomised trial. Lancet Oncol 2005 Jul;6(7):477–84.
- Braga M, Vignali A, Gianotti L, Zuliani W, Radaelli G, Gruarin P et al. Laparoscopic versus open colorectal surgery: a randomized trial on short-term outcome. Ann Surg 2002;236:759–766.
- Aziz O, Constantinides V, Tekkis PP, Athanasiou T, Purkayastha S, Paraskeva P et al. Laparoscopic versus open surgery for rectal cancer: a meta-analysis. Ann Surg Oncol 2006;13:413–424

# Πληροί η λαπαροσκοπική κολεκτομή τα ογκολογικά κριτήρια χειρουργικής εκτομής κακοήθων όγκων ;

**Current state of the art in laparoscopic colorectal surgery for cancer: Update on the multi-centric international trials**

Jennifer K Lee[1], Conor P Delaney[1] and Jeremy M Lipman[2]*

* Corresponding author: Jeremy M Lipman jlipman@metrohealth.org ▾ Author Affiliations

1 Department of Surgery, University Hospitals, Case Medical Center, Case Western Reserve University, Cleveland, OH, USA

2 Department of Surgery, MetroHealth Medical Center, Case Western Reserve University, Cleveland, OH, USA

For all author emails, please log on.

*Annals of Surgical Innovation and Research* 2012, **6**:5 doi:10.1186/1750-1164-6-5

The electronic version of this article is the complete one and can be found online at: http://www.asir-journal.com/content/6/1/5

Cochrane Database Syst Rev. 2014 Apr 15;4:CD005200. doi: 10.1002/14651858.CD005200.pub3.

**Laparoscopic versus open total mesorectal excision for rectal cancer.**

Vennix S[1], Pelzers L, Bouvy N, Beets GL, Pierie JP, Wiggers T, Breukink S.

Author Information

[1]Department of Surgery, Academic Medical Center, Meibergdreef 9, Amsterdam, Netherlands, 1105 AZ.

**Ογκολογική Ασφάλεια** (Cohrane Database Systematic Review 2014, ACS-National Surgical Quality Improvement Program)

Πολυκεντρικές Προοπτικές Τυχαιοποιημένες Συγκριτικές Μελέτες **(UK trial – MRC Clasicc Trial)** :

Βραχυπρόθεσμα προκύπτει ότι η λαπαροσκοπική προσπέλαση είναι το ίδιο αποτελεσματική όπως η ανοικτή, και ότι παρέχει τα ίδια μακροπρόθεσμα αποτελέσματα με αυτά της κλασσικής μεθόδου όσον αφορά τον καρκίνο του παχέος εντέρου.

- Καμία διαφορά αναφορικά με τον αριθμό των λεμφαδένων που αφαιρέθηκαν, την αναλογία των παρασκευασμάτων με όγκους σταδίου C2 κατά Duke's, καθώς και τον αριθμό των παρασκευασμάτων με θετικά περιφερικά όρια εκτομής
- Καλύτερη ολική αφαίρεση του δεξιού κόλου

# Πληροί η λαπαροσκοπική κολεκτομή τα ογκολογικά κριτήρια χειρουργικής εκτομής κακοήθων όγκων ;

**Have we improved in laparoscopic resection of rectal cancer: critical reflection on the early outcomes of COLOR II study**

Emad H Aly

Laparoscopic Colorectal Surgery & Training Unit, Aberdeen Royal Infirmary, Aberdeen, Scotland, United Kingdom

*Corresponding to:* Emad H Aly, M.B.B.Ch, MS, MD, FRCS, MEd. Consultant Colorectal Surgeon, Laparoscopic Colorectal Surgery & Training Unit, Aberdeen Royal Infirmary, Honorary Senior Lecturer, University of Aberdeen, Foresterhill, Aberdeen, AB25 2ZN, UK. Email: emad.aly@nhs.net.

Submitted Feb 19, 2013. Accepted for publication Mar 20, 2013.

doi: 10.3978/j.issn.2224-4778.2013.03.03

Surg Endosc (2015) 29:916–924
DOI 10.1007/s00464-014-3752-y

**Laparoscopic *versus* open resection for colon cancer: 10-year outcomes of a prospective clinical trial**

Marco E. Allaix · Giuseppe Giraudo · Massimiliano Mistrangelo · Alberto Arezzo · Mario Morino

Received: 26 February 2014 / Accepted: 11 July 2014 / Published online: 9 August 2014
© Springer Science+Business Media New York 2014

**Ογκολογική Ασφάλεια** (Cohrane Database Systematic Review 2014, ACS-National Surgical Quality Improvement Program)

**COLOR Trial** (COlon carcinoma Laparoscopic or Open Resection) :

Βραχυπρόθεσμα αποτελέσματα της COLOR είναι ότι με την λαπαροσκοπική προσπέλαση μπορεί να γίνει μια ασφαλής και ριζική εκτομή του καρκίνου του δεξιού, αριστερού και σιγμοειδούς κόλου καθώς και του ορθού.

- Καμιά διαφορά στον αριθμό των λεμφαδένων που αφαιρέθηκαν
- Καμία διαφορά ως προς το μήκος του κεντρικού και περιφερικού ορίου εκτομής του εντέρου μεταξύ των δύο μεθόδων
- Η περιεγχειρητική θνητότητα ≈ 30 ημέρες από την επέμβαση, δεν διέφερε μεταξύ των δυο μεθόδων

# Πληροί η λαπαροσκοπική κολεκτομή τα ογκολογικά κριτήρια χειρουργικής εκτομής κακοήθων όγκων ;

Ann Surg. 2007 Oct;246(4):655-62; discussion 662-4.

**Laparoscopic colectomy for cancer is not inferior to open surgery based on 5-year data from the COST Study Group trial.**

Fleshman J[1], Sargent DJ, Green E, Anvari M, Stryker SJ, Beart RW Jr, Hellinger M, Flanagan R Jr, Peters W, Nelson H; Clinical Outcomes of Surgical Therapy Study Group.

Ann Surg Oncol. 2011 Sep;18(9):2422-31. doi: 10.1245/s10434-011-1650-2. Epub 2011 Mar 31.

**Long-term follow-up and individual item analysis of quality of life assessments related to laparoscopic-assisted colectomy in the COST trial 93-46-53 (INT 0146).**

Stucky CC[1], Pookaj BA, Novotny PJ, Sloan JA, Sargent DJ, O'Connell MJ, Beart RW, Skibber JM, Nelson H, Weeks JC.

Surg Oncol Clin N Am. 2014 Jan;23(1):35-47. doi: 10.1016/j.soc.2013.09.006. Epub 2013 Oct 23.

**Controversies in laparoscopy for colon and rectal cancer.**

Mathis KL[1], Nelson H.

**Ογκολογική Ασφάλεια** (Cohrane Database Systematic Review 2014, ACS-National Surgical Quality Improvement Program)

**COST Trial** (Clinical Outcomes of Surgical Therapy) :

Η λαπαροσκοπική προσέγγιση δεν εμπεριέχει επιπλέον κινδύνους, όσον αφορά την επιβίωση και υποτροπή της νόσου, οδηγούν στο συμπέρασμα ότι πρέπει πλέον να θεωρείται μια αποδεκτή μέθοδος θεραπευτικής προσπέλασης του καρκίνου του παχέος εντέρου.

**End points :**

- 3ετής επιβίωση ελεύθερη νόσου
- 3ετής συνολικά επιβίωση

Bonjer H et al 2007

# Εκπόνηση των κατευθυντήριων οδηγιών (Guidelines) για την ασφαλή εκτέλεση λαπαροσκοπικών κολεκτομών

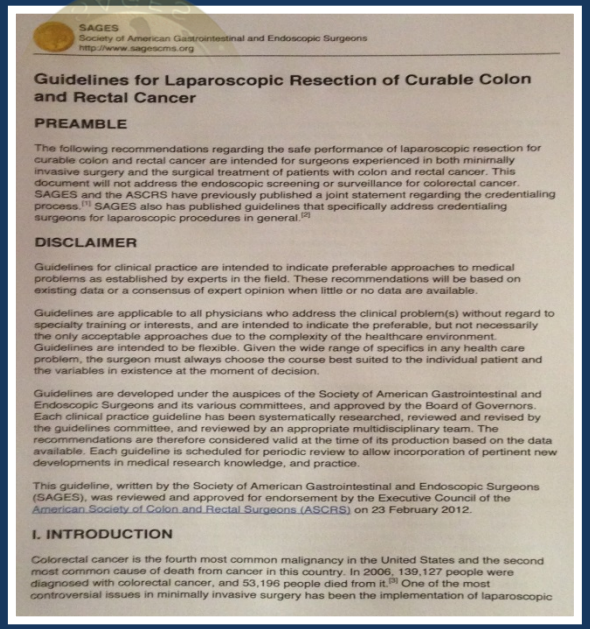

SAGES
Society of American Gastrointestinal and Endoscopic Surgeons
http://www.sagescms.org

## Guidelines for Laparoscopic Resection of Curable Colon and Rectal Cancer

### PREAMBLE

The following recommendations regarding the safe performance of laparoscopic resection for curable colon and rectal cancer are intended for surgeons experienced in both minimally invasive surgery and the surgical treatment of patients with colon and rectal cancer. This document will not address the endoscopic screening or surveillance for colorectal cancer. SAGES and the ASCRS have previously published a joint statement regarding the credentialing process.[1] SAGES also has published guidelines that specifically address credentialing surgeons for laparoscopic procedures in general.[2]

### DISCLAIMER

Guidelines for clinical practice are intended to indicate preferable approaches to medical problems as established by experts in the field. These recommendations will be based on existing data or a consensus of expert opinion when little or no data are available.

Guidelines are applicable to all physicians who address the clinical problem(s) without regard to specialty training or interests, and are intended to indicate the preferable, but not necessarily the only acceptable approaches due to the complexity of the healthcare environment. Guidelines are intended to be flexible. Given the wide range of specifics in any health care problem, the surgeon must always choose the course best suited to the individual patient and the variables in existence at the moment of decision.

Guidelines are developed under the auspices of the Society of American Gastrointestinal and Endoscopic Surgeons and its various committees, and approved by the Board of Governors. Each clinical practice guideline has been systematically researched, reviewed and revised by the guidelines committee, and reviewed by an appropriate multidisciplinary team. The recommendations are therefore considered valid at the time of its production based on the data available. Each guideline is scheduled for periodic review to allow incorporation of pertinent new developments in medical research knowledge, and practice.

This guideline, written by the Society of American Gastrointestinal and Endoscopic Surgeons (SAGES), was reviewed and approved for endorsement by the Executive Council of the American Society of Colon and Rectal Surgeons (ASCRS) on 23 February 2012.

### I. INTRODUCTION

Colorectal cancer is the fourth most common malignancy in the United States and the second most common cause of death from cancer in this country. In 2006, 139,127 people were diagnosed with colorectal cancer, and 53,196 people died from it.[3] One of the most controversial issues in minimally invasive surgery has been the implementation of laparoscopic

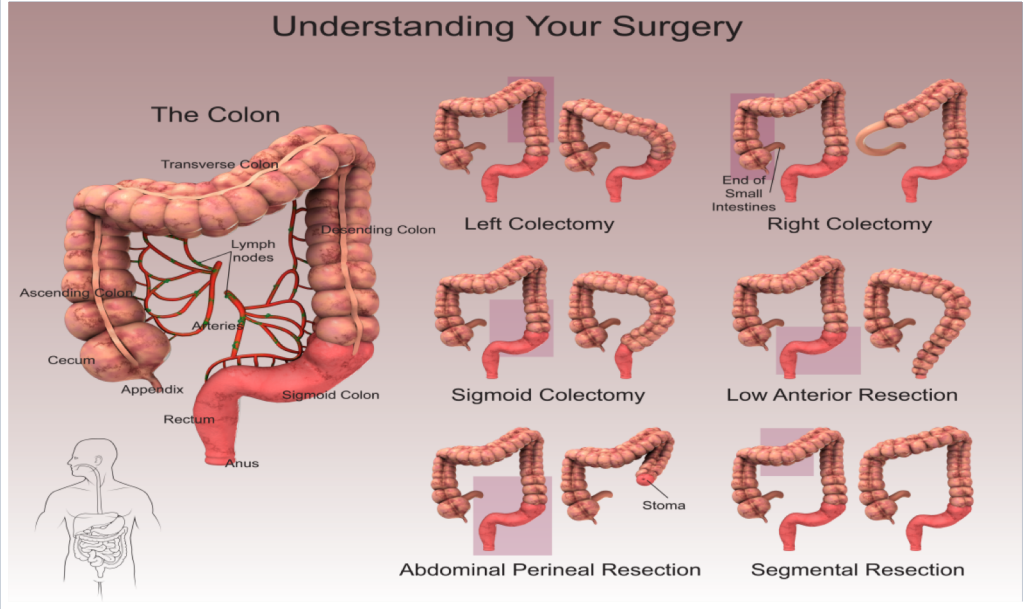

# Ανατομία παχέος εντέρου:

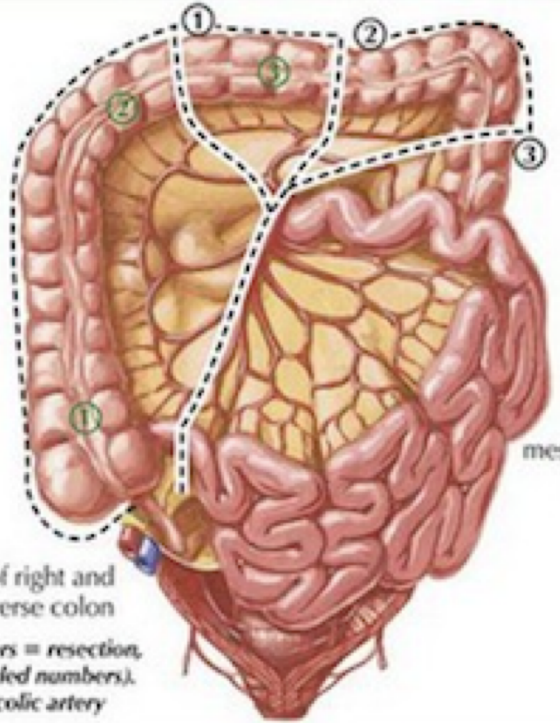


Lesions of right and transverse colon

*Dashed lines and black circled numbers = resection, depending on site of lesion (green circled numbers). Note inclusion of branches of middle colic artery depending on location of tumor.*

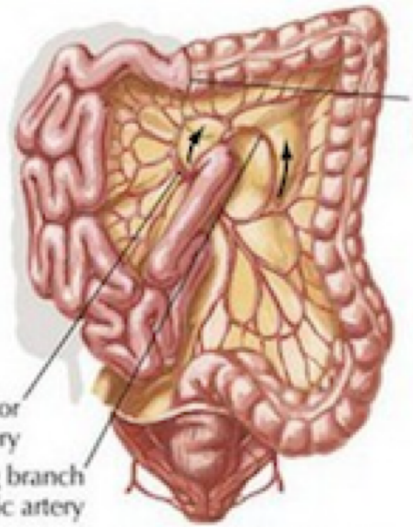


Partial colectomy for cancer of right colon removes cancer and mesenteric lymphatic drainage, while preserving supply based on remaining branches of superior mesenteric artery or ascending branch of left colic artery.

# Ανατομία παχέος εντέρου – αγγεία, νεύρα, λεμφογάγγλια:

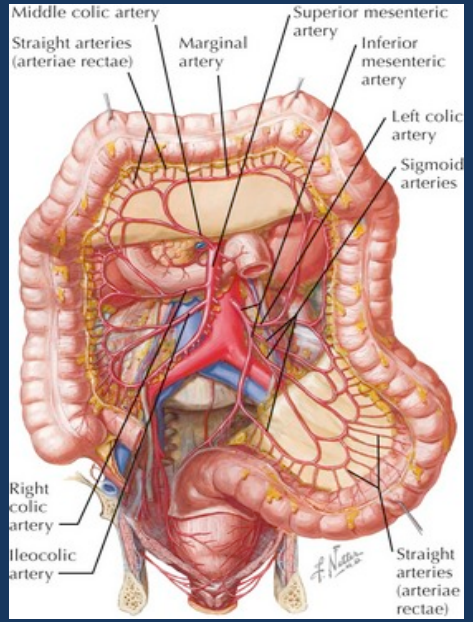


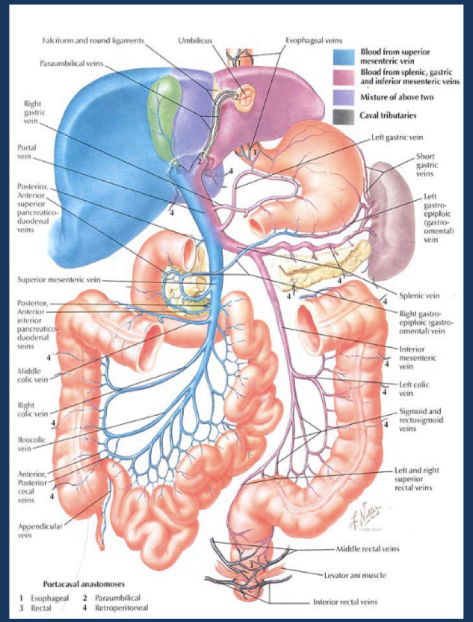


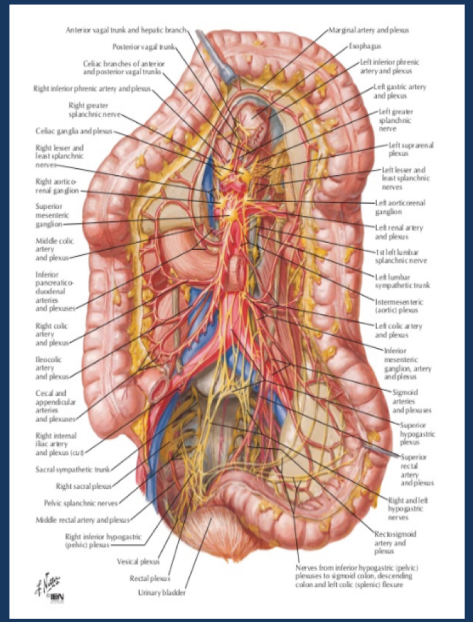


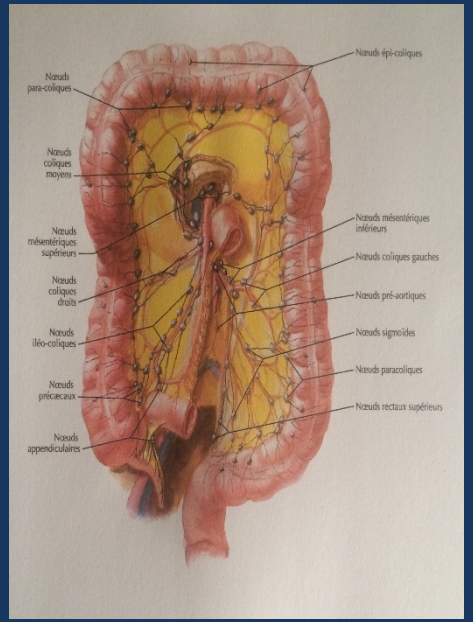

# Τεχνικές κινητοποίησης δεξιού κόλου:

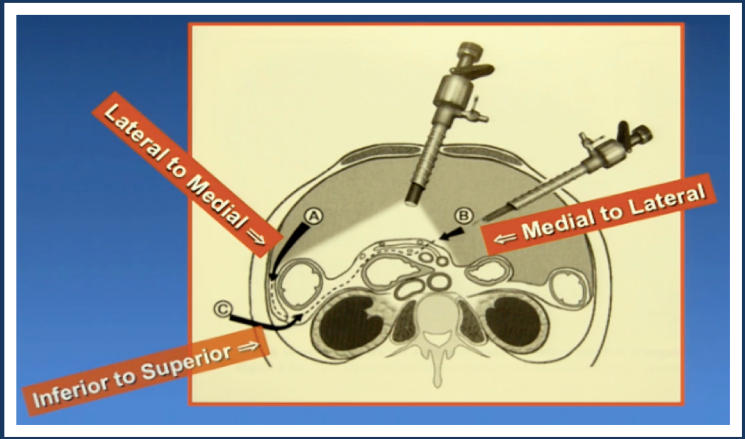


- Medial-to-lateral παρασκευή δεξιού κόλου
- Lateral-to-medial παρασκευή δεξιού κόλου
- Inferior-to-superior παρασκευή δεξιού κόλου
- Top down παρασκευή δεξιού κόλου

# Θέση:

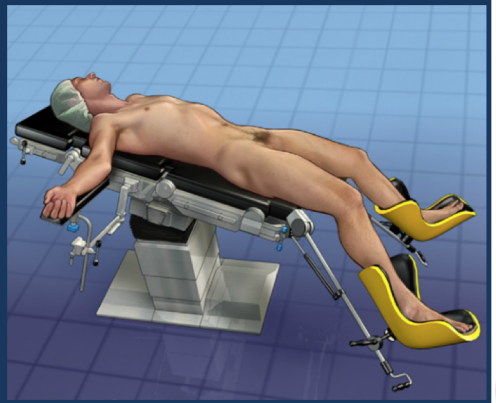

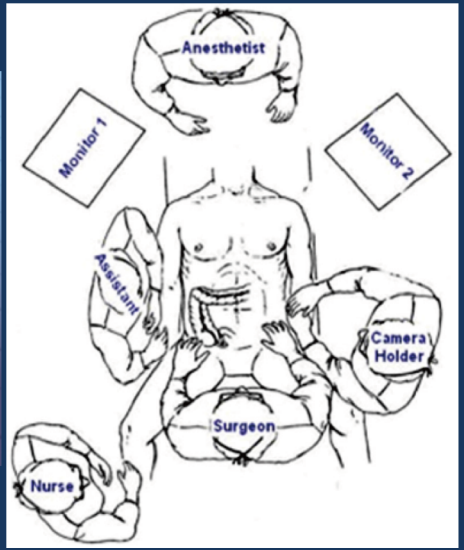
Anesthetist
Monitor 1
Monitor 2
Assistant
Camera Holder
Surgeon
Nurse

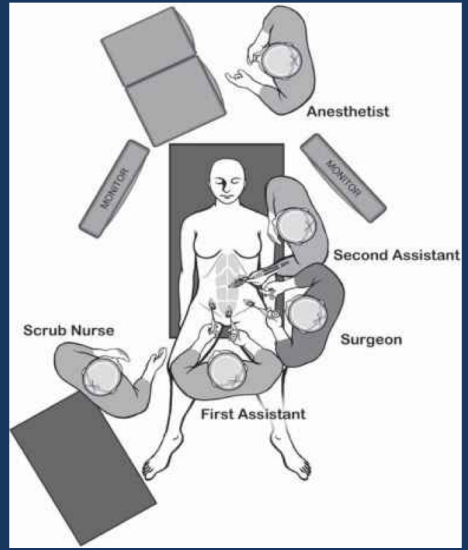
Anesthetist
MONITOR
MONITOR
Second Assistant
Scrub Nurse
Surgeon
First Assistant

# Τοποθέτηση τροκάρ στις ακόλουθες θέσεις: (Medial-to-lateral/ Lateral-to-medial/ Inferior-to-superior)

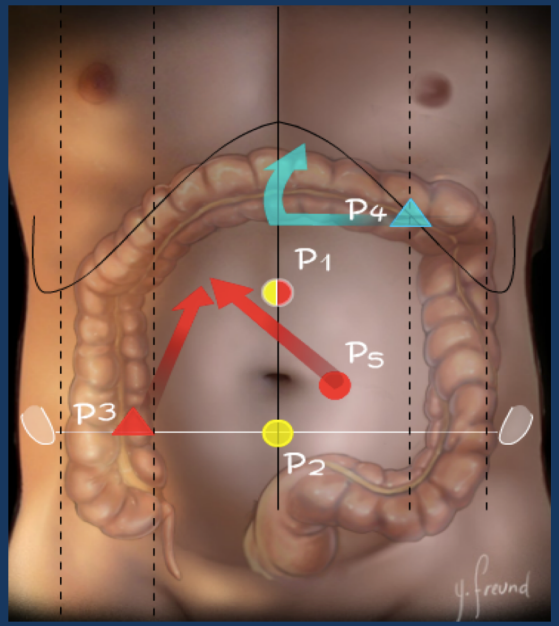




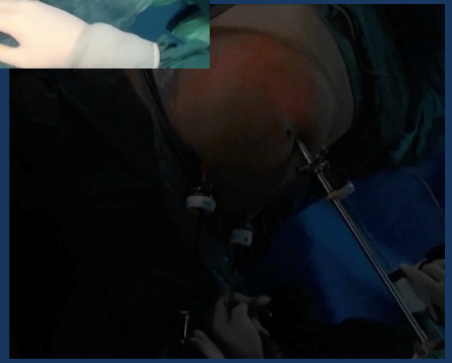

**VASILEIOS DRAKOPOULOS** MD, PhD, FACS
www.vasileiosdrakopoulos.com

# Medial-to-lateral παρασκευή δεξιού κόλου:

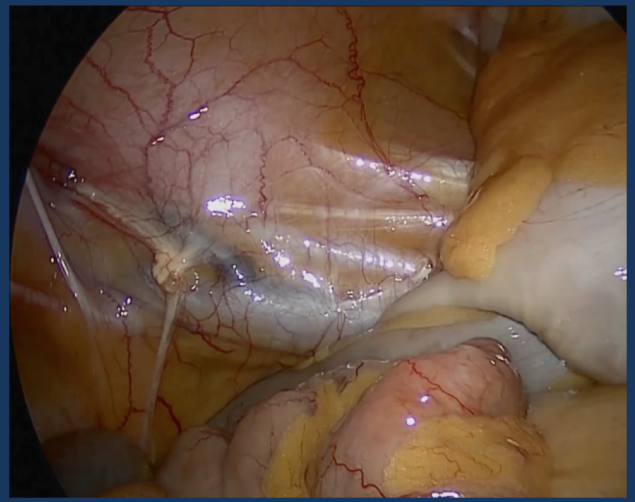

# Medial-to-lateral παρασκευή δεξιού κόλου:

- Αποκάλυψη της ρίζας του δεξιού μοσοκόλου
- Αναγνώριση – Απολίνωση - Διατομή
  - Δεξιών κολικών αγγείων
  - Δεξιών κλάδων των μέσων κολικών αγγείων
  - Ειλεοκολικών αγγείων (αρχή της ειλεοκολικής αρτηρίας από την άνω μεσεντέριο)

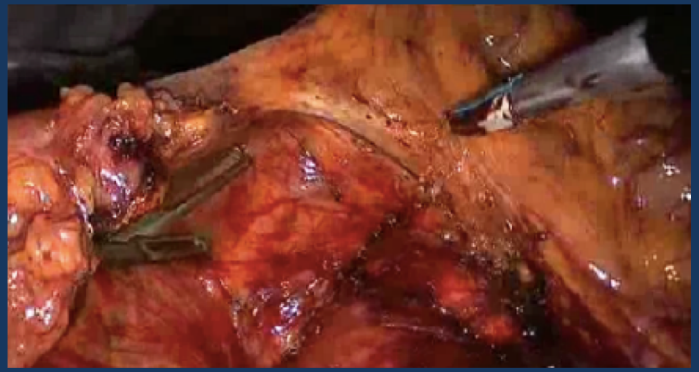

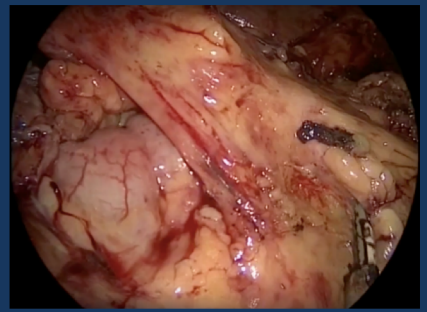

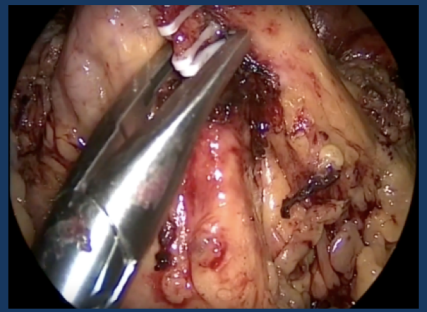

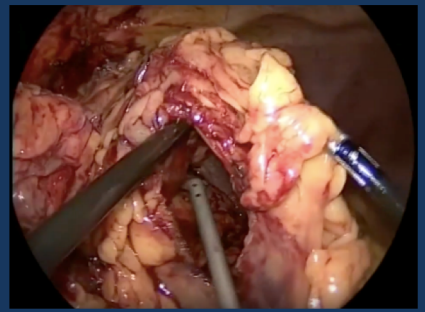

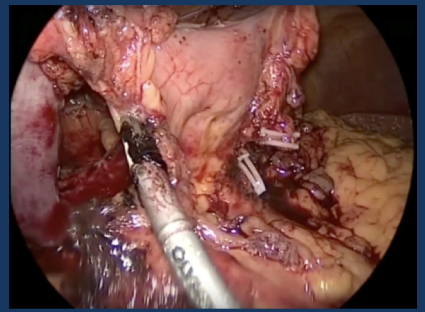

# Medial-to-lateral παρασκευή δεξιού κόλου:

- Παρασκευή–Διαχωρισμός δεξιού μεσόκολου από το οπισθοπεριτόναιο
- Αναγνώριση–Απολίνωση-Διατομή
  - κλάδου της μέσης κολικής αρτηρίας προς την ηπατική καμπή
- Διατομή της ανάκαμψης του τοιχωματικού περιτοναίου (γραμμή Toldt)
- Κινητοποίησης τελικού ειλεού, δεξιού κόλου και μεσόκολου

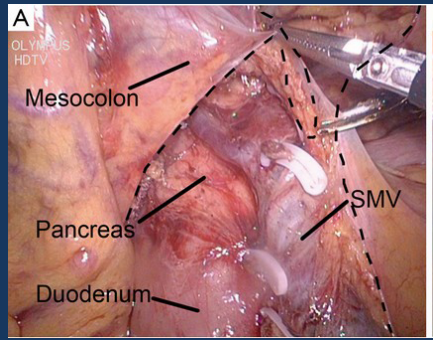


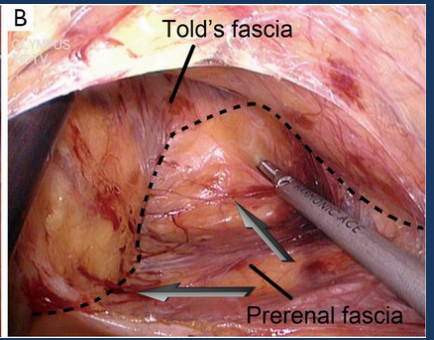


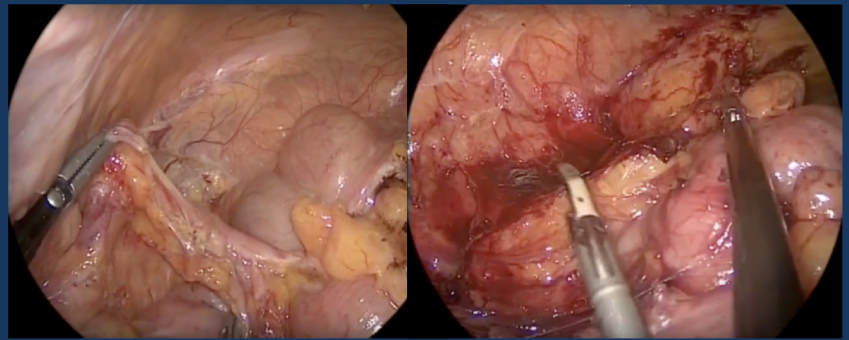

**VASILEIOS DRAKOPOULOS** MD, PhD, FACS

# Laparoscopic Right Hemicolectomy: Medial-to-Lateral approach Colon mobilization and Vessel Ligation

**District General Hospital of Athens "Evangelismos" - Greece**
1st Department of Surgery and Transplantation Unit

## Lateral-to-medial παρασκευή δεξιού κόλου:

- Διατομή του περιτοναίου κατά μήκος της γραμμής του Toldt (έως το ύψος της ηπατικής καμπής)
- Κινητοποίηση-Ανάσπαση του δεξιού κόλου
- Διατομή του περιτοναίου κατά μήκος της ρίζας του μεσοκόλου
- Απολίνωση-Διατομή αγγειακών στελεχών δεξιού κόλου

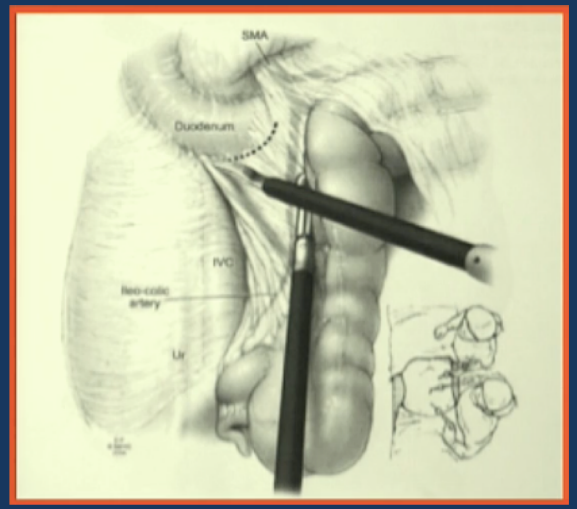


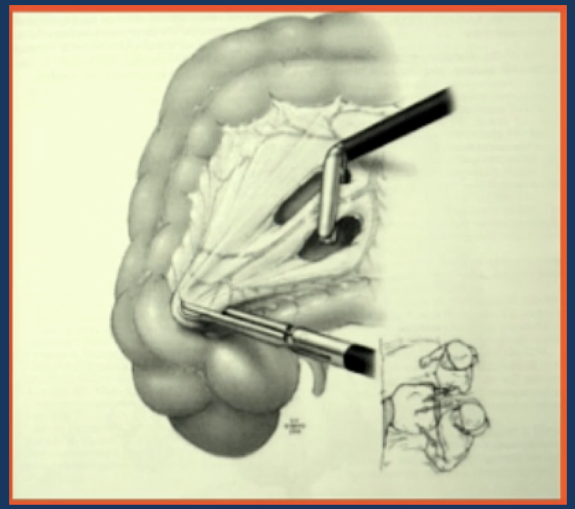

# Lateral-to-medial παρασκευή δεξιού κόλου:

- Διατομή του περιτοναίου κατά μήκος της γραμμής του Toldt (έως το ύψος της ηπατικής καμπής)
- Κινητοποίηση-Ανάσπαση του δεξιού κόλου

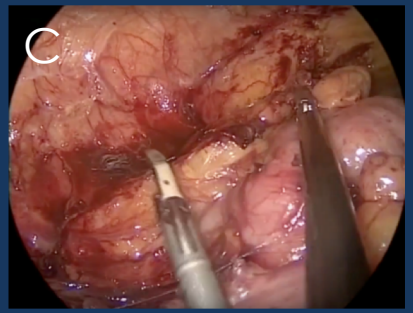


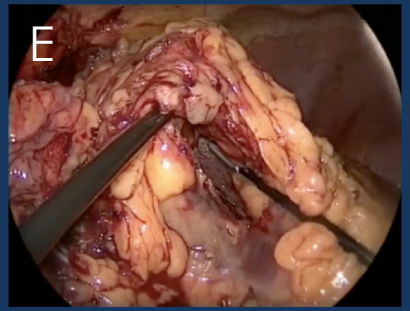


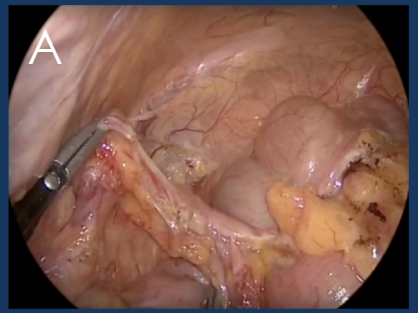


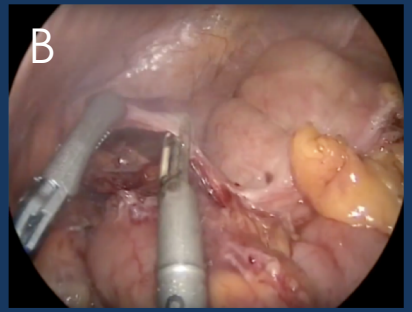


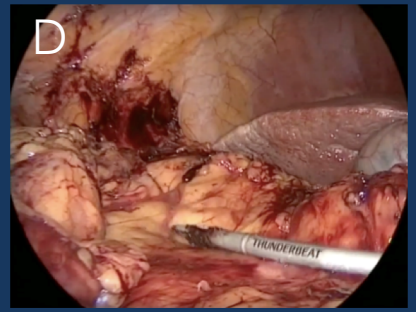


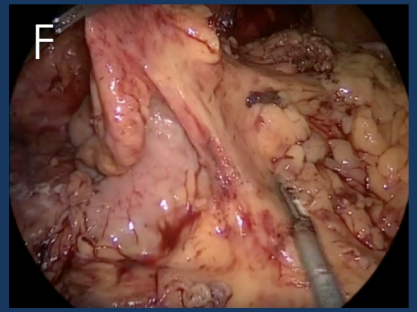

# Lateral-to-medial παρασκευή δεξιού κόλου:

- Διατομή του περιτοναίου κατά μήκος της ρίζας του μεσοκόλου
- Απολίνωση-Διατομή αγγειακών στελεχών δεξιού κόλου

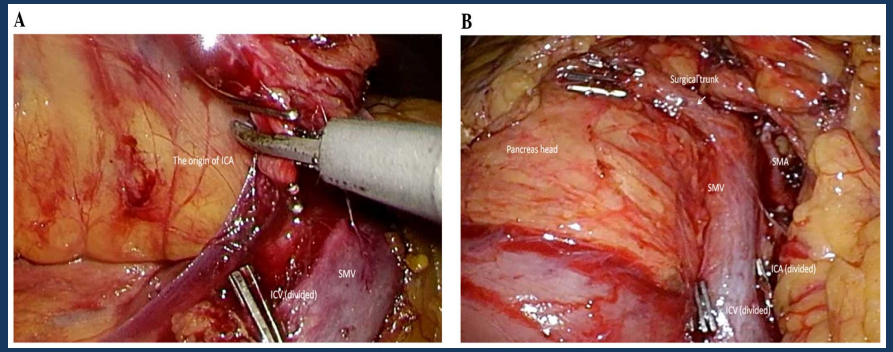


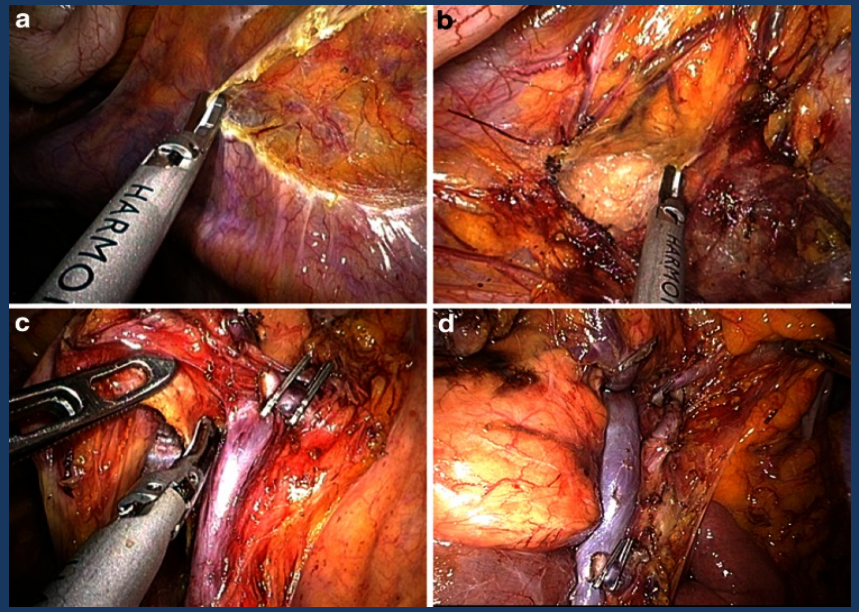

**VASILEIOS DRAKOPOULOS** MD, PhD, FACS

# Laparoscopic Right Hemicolectomy: Lateral-to-Medial approach Colon mobilization and Vessel Ligation

**District General Hospital of Athens "Evangelismos" - Greece**
1st Department of Surgery and Transplantation Unit

# Inferior-to-superior παρασκευή δεξιού κόλου:

- Νόσος του Crohn
- Περιπτώσεις πολλαπλών ισχυρών συμφύσεων

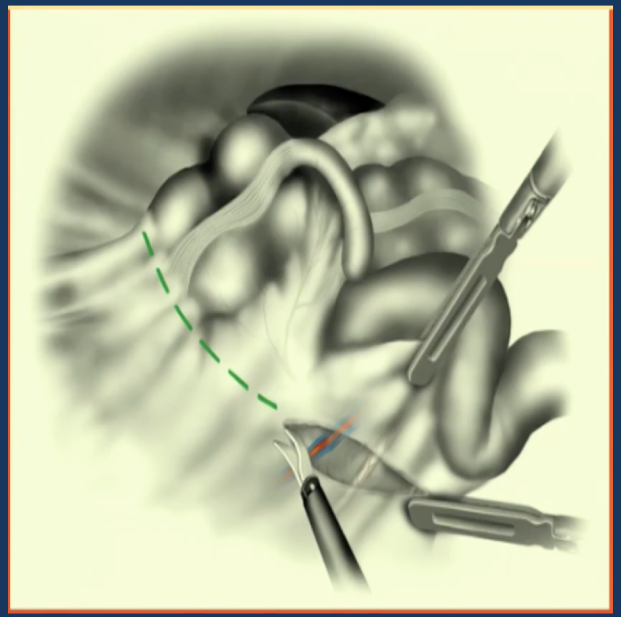

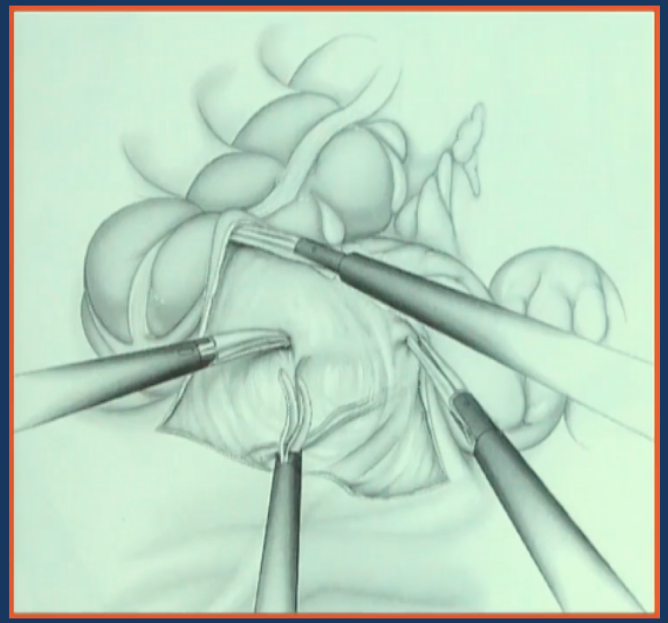

# Top-down παρασκευή δεξιού κόλου:

- Παχύσαρκοι ασθενείς

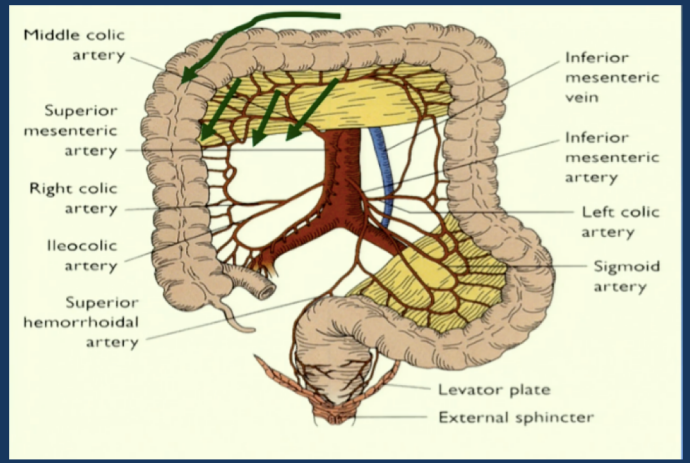


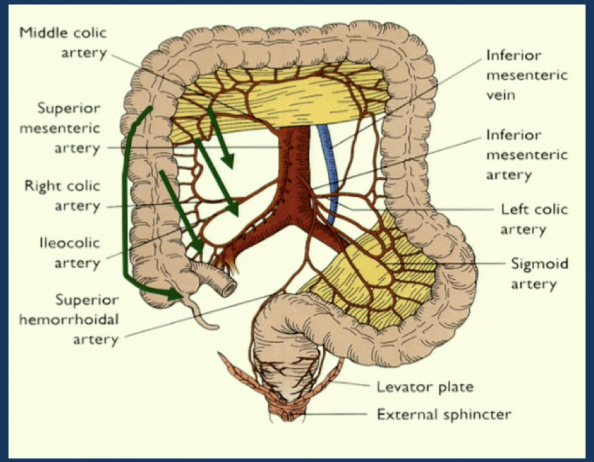


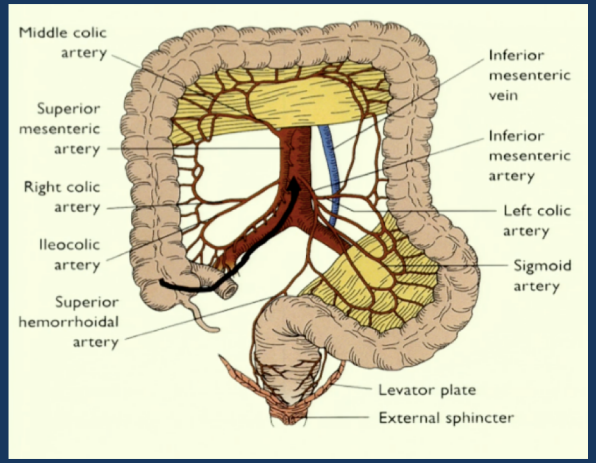

# Τοποθέτηση τροκάρ στις ακόλουθες θέσεις:

- Top-down

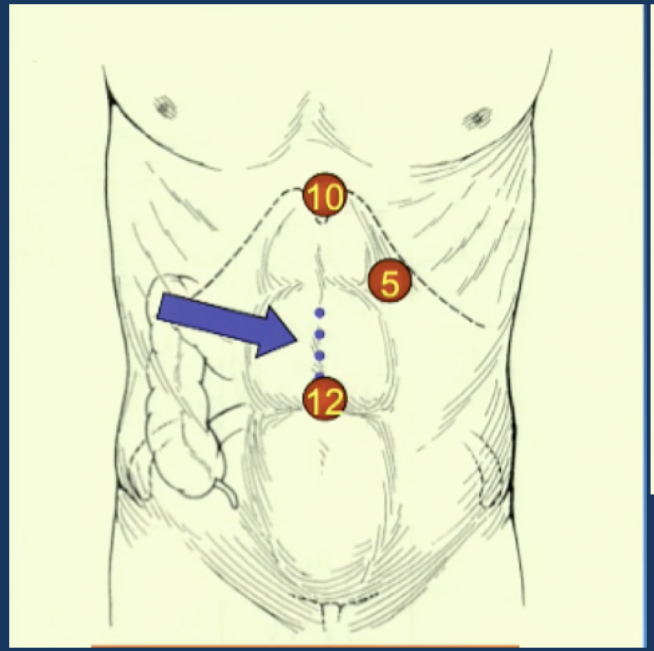


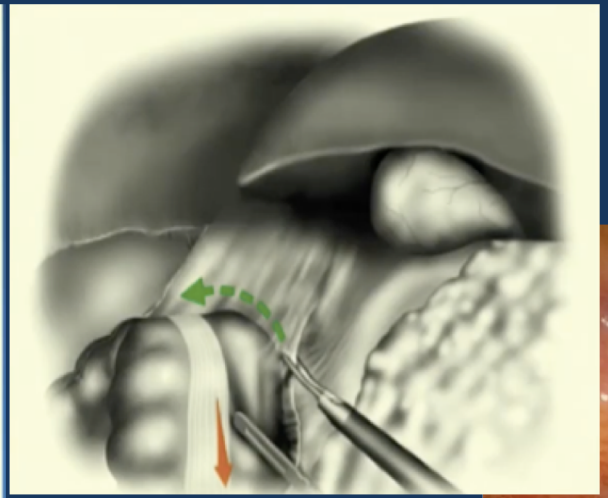

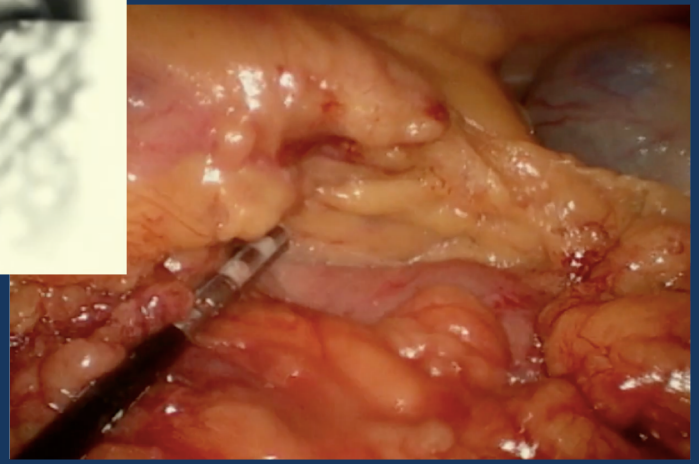

## Ειδικά σημεία ενδιαφέροντος:

- Σύστοιχου ουρητήρα
- Έσω σπερματικά αγγεία
- Κάτω κοίλη φλέβας
- Εξωηπατικά χοληφόρα-Ηπατική κάψα-Χοληδόχος κύστη
- Οπισθοπεριτοναϊκής μοίρας του δωδεκαδακτύλου
- Αποκάλυψη της κεφαλής του παγκρέατος
  - → Επάρκεια της παρασκευής του δωδεκαδάκτυλου
  - → Ασφαλής απολίνωση των δεξιών κλάδων των μέσων κολικών αγγείων

# Τεχνικές κινητοποίησης δεξιού κόλου:


Tech Coloproctol. 2017 Sep 4. doi: 10.1007/s10151-017-1672-2. [Epub ahead of print]

**Three steps and a join: a simple guide to right- and left-sided medial to lateral laparoscopic colorectal surgery.**

Rickard MJFX[1,2], Keshava A[1,2], Toh JWT[3,4].

Int J Colorectal Dis. 2016 Mar;31(3):631-4. doi: 10.1007/s00384-015-2499-9. Epub 2016 Jan 22.

**A medial to lateral approach offers a superior lymph node harvest for laparoscopic right colectomy.**

Honaker M[1], Scouten S[2], Sacksner J[2], Ziegler M[2], Wasvary H[2].

World J Gastroenterol. 2014 Aug 14;20(30):10531-6. doi: 10.3748/wjg.v20.i30.10531.

**Techniques and feasibility of laparoscopic extended right hemicolectomy with D3 lymphadenectomy.**

Zhao LY[1], Liu H[1], Wang YN[1], Deng HJ[1], Xue Q[1], Li GX[1].

Zhonghua Wei Chang Wai Ke Za Zhi. 2010 Jun;13(6):403-5.

**[A prospective randomized control trial of the approach for laparoscopic right hemi-colectomy:medial-to-lateral versus lateral-to-medial].**

[Article in Chinese]
Yan J[1], Ying MG, Zhou D, Chen X, Chen LC, Ye WF, Zang WD.

Surg Laparosc Endosc Percutan Tech. 2009 Feb;19(1):43-7. doi: 10.1097/SLE.0b013e31818e91f3.

**Laparoscopic colectomy: medial versus lateral approach.**

Rotholtz NA[1], Bun ME, Tessio M, Lencinas SM, Laporte M, Aued ML, Peczan CE, Mezzadri NA.


## Medial-to-lateral Vs Lateral-to-medial:

- Καλύτερο εγχειρητικό πεδίο
- Πληρέστερο λεμφαδενικό καθαρισμό
- Λιγότερη απώλεια αίματος
- Μικρότερος εχειρητικός χρόνος
- Ευκολότερα Αναπαραγώγιμη

## Inferior-to-superior:

- Νόσος του Crohn
- Περιπτώσεις πολλαπλών ισχυρών συμφύσεων

## Top-down:

- Παχύσαρκοι ασθενείς

## Anastomosis for Laparoscopic Right Colectomy:

**Intracorporeal (ICA)**

**Vs**

**Extracorporeal (ECA)**

**VASILEIOS DRAKOPOULOS** MD, PhD, FACS

# Laparoscopic Right Hemicolectomy: Intracorporeal Anastomosis

**District General Hospital of Athens "Evangelismos" - Greece**
1st Department of Surgery and Transplantation Unit

**VASILEIOS DRAKOPOULOS** MD, PhD, FACS

# Laparoscopic Right Hemicolectomy: Extracorporeal Anastomosis

**District General Hospital of Athens "Evangelismos" - Greece**
1st Department of Surgery and Transplantation Unit

# Anastomosis for Laparoscopic Right Colectomy:


Surg Endosc. 2019 Oct 23. doi: 10.1007/s00464-019-07204-z. [Epub ahead of print]

**Intracorporeal versus extracorporeal anastomosis for right colectomy does not affect gastrointestinal recovery within an enhanced recovery after surgery program.**

Trépanier M[1,2], Valin-Thorburn A[3], Kouyoumdjian A[3], Dumitra T[1,2], Alhashemi M[1,2], Kaneva P[2], Liberman AS[1,2], Charlebois P[1,2], Stein BS[1,2], Fried GM[1,2], Feldman LS[1,2], Lee L[4,5].

Ann Surg. 2019 Nov;270(5):762-767. doi: 10.1097/SLA.0000000000003519.

**Intracorporeal or Extracorporeal Ileocolic Anastomosis After Laparoscopic Right Colectomy: A Double-blinded Randomized Controlled Trial.**

Allaix ME[1], Degiuli M[1], Bonino MA[1], Arezzo A[1], Mistrangelo M[1], Passera R[2], Morino M[1].

Dig Surg. 2018;35(3):236-242. doi: 10.1159/000479241. Epub 2017 Aug 3.

**Intracorporeal versus Extracorporeal Anastomoses Following Laparoscopic Right Colectomy in Obese Patients: A Case-Matched Study.**

Vignali A[1], Elmore U, Lemma M, Guarnieri G, Radaelli G, Rosati R.

Int J Colorectal Dis. 2018 Mar;33(3):291-298. doi: 10.1007/s00384-017-2957-7. Epub 2018 Jan 11.

**Does laparoscopic intracorporeal ileocolic anastomosis decreases surgical site infection rate? A propensity score-matched cohort study.**

Martinek L[1], You K[2], Giuratrabocchetta S[2], Gachabayov M[2], Lee K[2], Bergamaschi R[3].

Zhonghua Wei Chang Wai Ke Za Zhi. 2017 Aug 25;20(8):891-895.

**[Comparison of intra-abdominal infection between intracorporeal anastomosis and extracorporeal anastomosis in patients undergoing laparoscopic right hemicolectomy].**

[Article in Chinese]
Sun X, Qiu H, Fei K, Xu L, Lu J, Zhang G, Xiao Y[1].


## Intracorporeal vs Extracorporeal Anastomosis :

- ICA is associated with earlier recovery of postoperative bowel function than ECA.
- ICA is associated with improved short- and long-term outcomes. The rates of postoperative complications requiring intervention and incisional hernias are decreased especially in obese patients.
- ICA reduced incisional SSI rates as compared to its ECA counterpart.
- ICA anastomosis could be considered a valuable option in the hands of expert surgeons, with favorable effect on recovery of bowel function and postoperative ileus.

# Right Colectomy with Complete Mesocolic Excision: Four-arm Technique

Giuseppe Spinoglio, Alessandra Marano, Fabio Priora, Ferruccio Ravazzoni, and Giampaolo Formisano

13 Right Colectomy with Complete Mesocolic Excision: Four-arm Technique 127

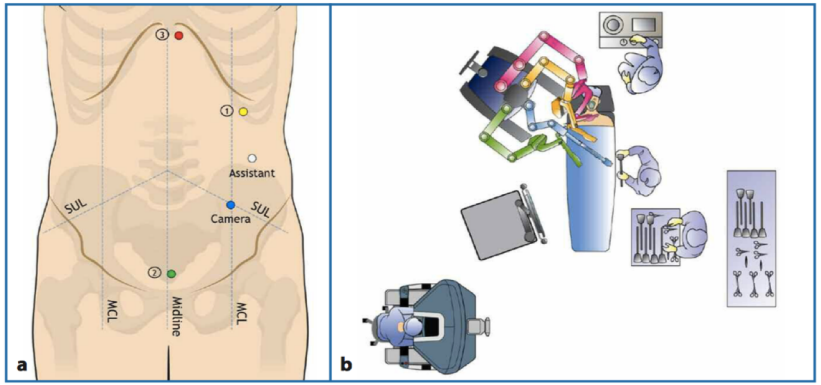


**Fig. 13.1** Robotic right colectomy. **a** Trocar layout. **b** Overhead view of OR setup. (© 2014 Intuitive Surgical, Inc.)

# Απολίνωση αγγείων:

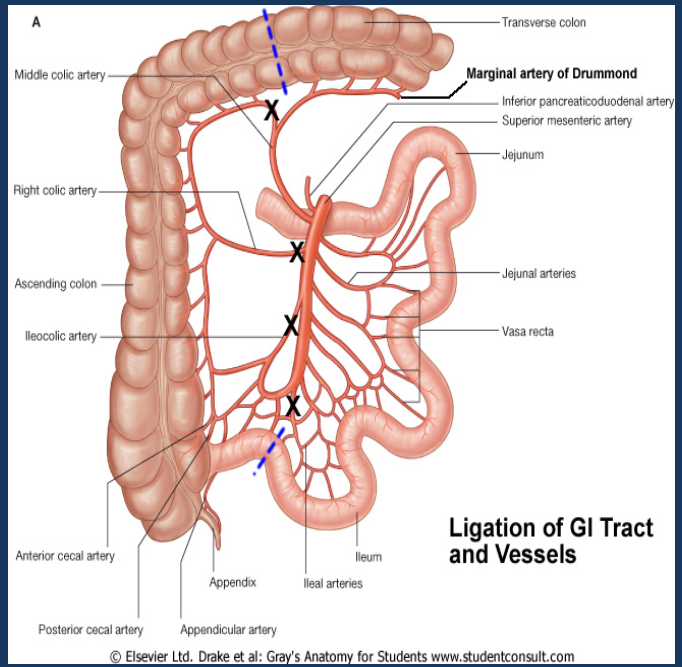


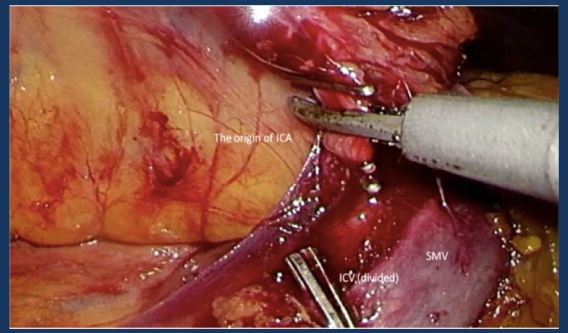


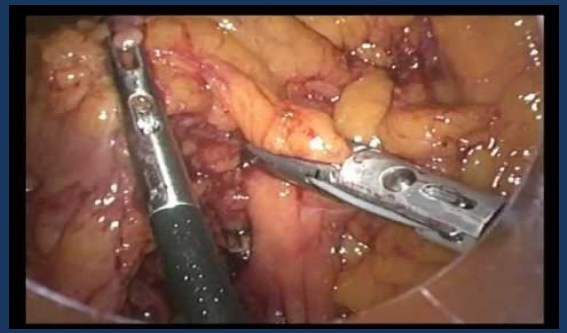

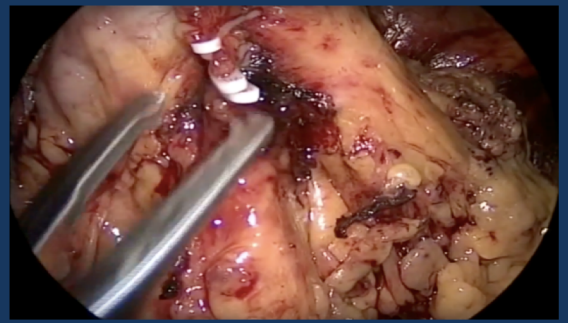

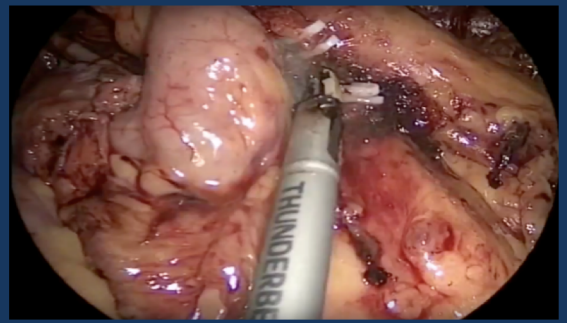

# Ανατομικές παραλλαγές αγγείων:

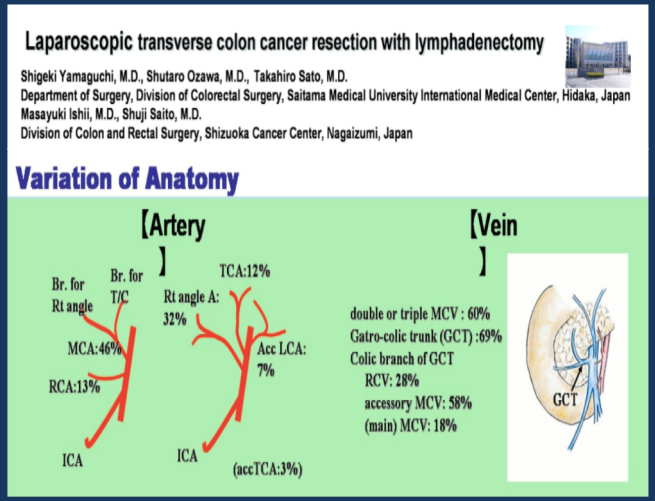


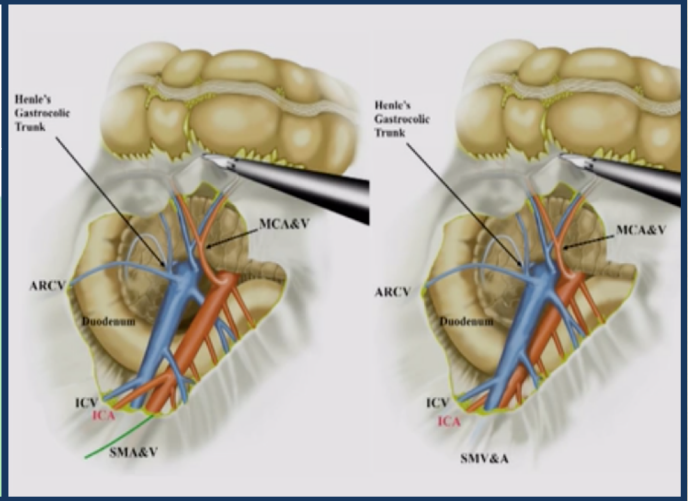


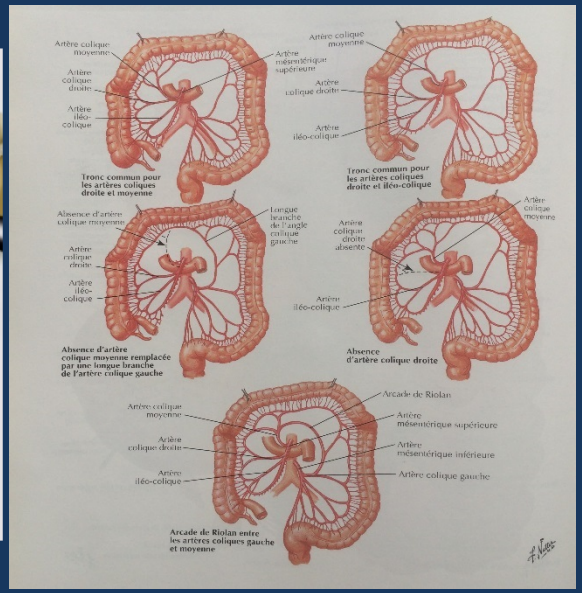

# Ανατομικές παραλλαγές αγγείων:

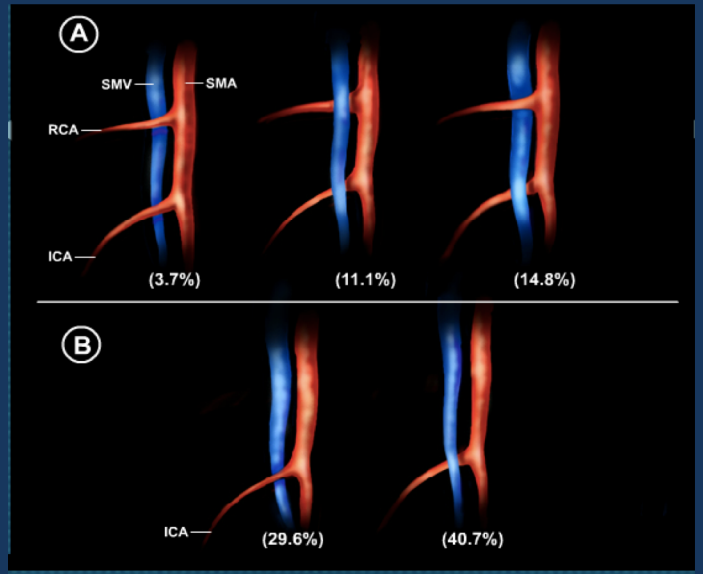


There are several anatomical variations concerning the right colic vessels.
See schematics of the right colic artery (RCA), ileocolic artery (ICA), superior mesenteric artery (SMA) and superior mesenteric vein (SMV).
A and B: positioning of the right colic arteries in relation to the SMV (Shatari et al., 2003)
A, with RCA; B, without RCA.

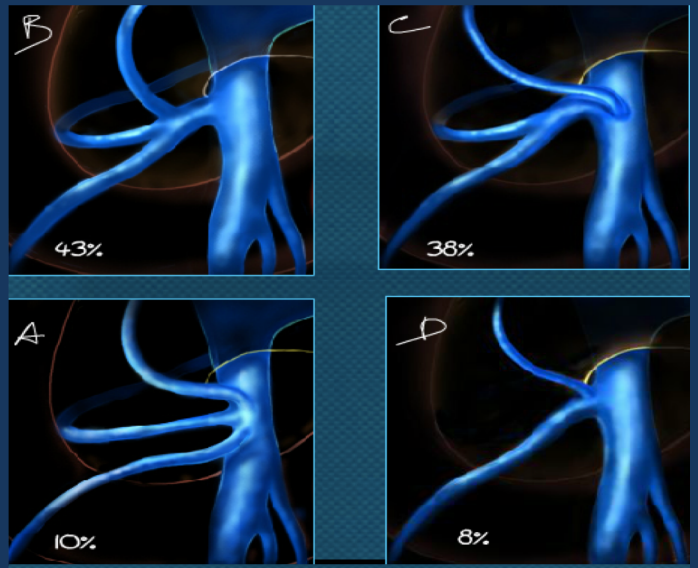


(Mori et al., 1992; Lange et al., 2000)
There are several anatomical variations in the number and position of the vessels (see A, B, C, D). In the study by Lange et al., the CT-scan highlights that the gastrocolic trunk is not present in 10% of patients.

# Indocyanine green (ICG) – enhanced fluorescence:

Surg Endosc. 2016 Jul;30(7):2736-42. doi: 10.1007/s00464-015-4540-z. Epub 2015 Oct 20.

**Indocyanine green-enhanced fluorescence to assess bowel perfusion during laparoscopic colorectal resection.**

Boni L[1], David G[2], Dionigi G[2], Rausei S[2], Cassinotti E[2], Fingerhut A[3,4].

Annals of Surgical Oncology
February 2016, Volume 23, Supplement 2, pp 266–274 | Cite as

**Visualization of Lymph/Blood Flow in Laparoscopic Colorectal Cancer Surgery by ICG Fluorescence Imaging (Lap-IGFI)**

Authors Authors and affiliations
Naoto Nishigori, Fumikazu Koyama, Tadashi Nakagawa, Shinji Nakamura, Takeshi Ueda, Takashi Inoue, Keijirou Kawasaki, Shinsaku Obara, Takayuki Nakamoto, Hisao Fujii, Yoshiyuki Nakajima

Surg Endosc. 2016; 30: 2736–2742. PMCID: PMC4912584
Published online 2015 Oct 20. doi: 10.1007/s00464-015-4540-z

**Indocyanine green-enhanced fluorescence to assess bowel perfusion during laparoscopic colorectal resection**

Luigi Boni, Giulia David, Gianlorenzo Dionigi, Stefano Rausei, Elisa Cassinotti, and Abe Fingerhut

Author information ► Article notes ► Copyright and License information ►

Am Surg. 2015 Jun;81(6):580-4.

**Intraoperative indocyanine green fluorescence angiography--an objective evaluation of anastomotic perfusion in colorectal surgery.**

Protyniak B[1], Dinallo AM, Boyan WP Jr, Dressner RM, Arvanitis ML.

Surg Endosc. 2015; 29(7): 2046–2055. PMCID: PMC4471386
Published online 2014 Oct 11. doi: 10.1007/s00464-014-3895-x

**Clinical applications of indocyanine green (ICG) enhanced fluorescence in laparoscopic surgery**

Luigi Boni, Giulia David, Alberto Mangano, Gianlorenzo Dionigi, Stefano Rausei, Sebastiano Spampatti, Elisa Cassinotti, and Abe Fingerhut

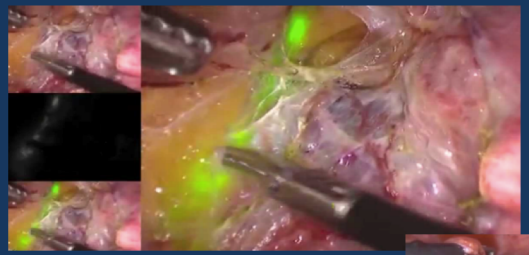

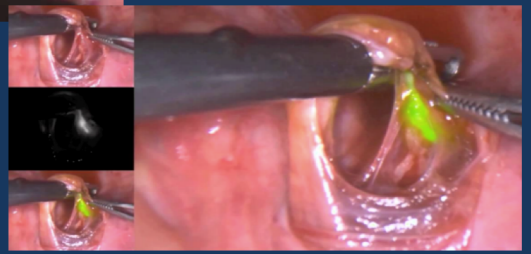



## Εφαρμογή της μεθόδου σε ειδικές ομάδες ασθενών:

- Παχυσαρκία
- Ιστορικό προηγούμενων πολλαπλών επεμβάσεων στην κοιλιά (συμφύσεις)
- Αιμορραγικά προβλήματα κατά τη διάρκεια της επέμβασης

→ Η χειρουργική εμπειρία σε μεγάλη σειρά λαπαροσκοπικών κολεκτομών δίνει τη δυνατότητα για ασφαλή εκτέλεση των περισσότερων επεμβάσεων λαπαροσκοπικά.

## Παρελθόν

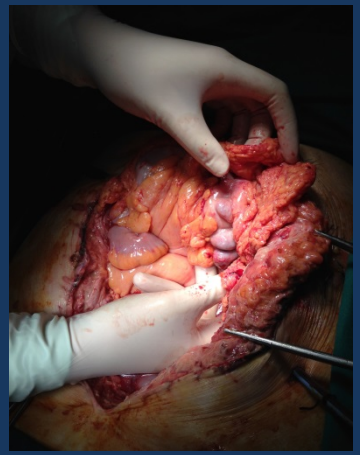

## Παρόν

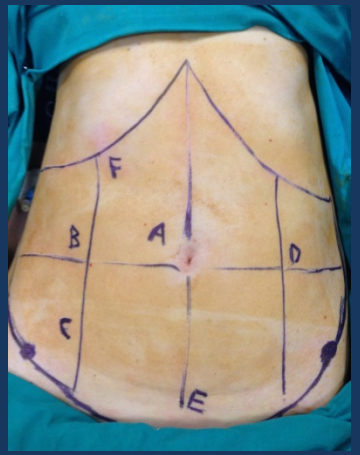


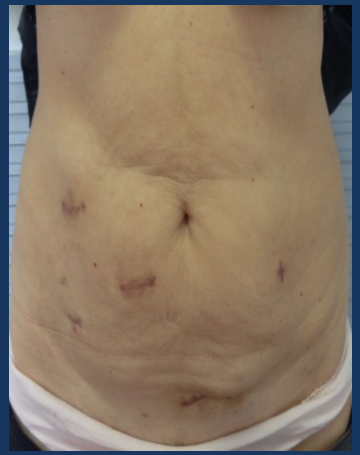

## Μέλλον

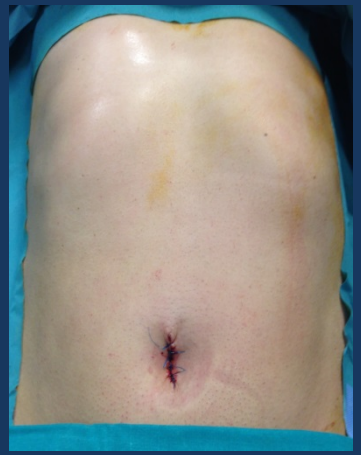

# Ερωτήσεις

## Συμπεράσματα:

Βάσει της διεθνούς βιβλιογραφίας η (ΔΕ) λαπαροσκοπική κολεκτομή (Medial-to-lateral/ lateral-to-medial/ inferior-to-superior/ Top-down) είναι :

1. Απόλυτα ασφαλής και αποτελεσματική και πληροί απόλυτα τα ογκολογικά κριτήρια.
2. Τήρηση των κατευθυντήριων οδηγιών (guidelines) για σωστή κινητοποίηση του δεξιού κόλου και απολίωνση των αγγείων.
3. Ιδιαίτερη προσοχή σε: σύστοιχο ουρητήρα, έσω σπερματικά αγγεία, κάτω κοίλη φλέβας, εξωηπατικά χοληφόρα- ηπατική κάψα – χοληδόχο κύστη, οπισθοπεριτοναϊκή μοίρα του δωδεκαδάκτυλου, αποκάλυψη της κεφαλής του παγκρέατος)
4. Η ασφάλεια και τα καλά αποτελέσματα της μεθόδου καταδεικνύονται από την ολοένα και μεγαλύτερη στροφή των χειρουργών παγκοσμίως προς αυτήν.
5. Medial-to-lateral Vs Lateral-to-medial
6. Intracorporeal vs Extracorporeal.

Βασίλειος Δρακόπουλος MD, PhD, FACS
Χειρουργός
Α' Χειρουργική Κλινική – Μονάδα Μεταμοσχεύσεων Οργάνων
Γ.Ν.Α. «ο Ευαγγελισμός»